

Bone sarcomas: ESMO Clinical Practice Guidelines for diagnosis, treatment and follow-up[†]

The ESMO/European Sarcoma Network Working Group*

incidence

Primary bone tumours are rare, accounting for <0.2% of malignant tumours registered in the EURO CARE database [1]. Different tumours have distinct patterns of incidence. Osteosarcoma and Ewing sarcoma (ES) have a relatively high incidence in the second decade of life, whereas chondrosarcomas are more common in older age groups (Figure 1).

Osteosarcoma is the most frequent primary cancer of bone (incidence: 0.2–0.3/100 000/year). The incidence is higher in adolescents (0.8–1.1/100 000/year at age 15–19), where it accounts for >10% of all solid cancers. The male:female ratio is 1.4:1. Risk factors for the occurrence of osteosarcoma include previous radiation therapy, Paget disease of bone [2], and germline abnormalities, such as Li–Fraumeni syndrome, Werner syndrome, Rothmund–Thomson syndrome, Bloom syndrome, and hereditary retinoblastoma [3].

ES is the third most common primary malignant bone-associated sarcoma. It occurs most frequently in children and adolescents, but is also seen in adults. Median age at diagnosis is 15 years and there is a male predilection of 1.5:1. In white Caucasians under the age of 25, ES has an incidence of 0.3/100 000 per year [4], but it is very uncommon in the African and Asian population. About 25% of patients have ES of the pelvic bones, whereas 50% have extremity tumours. The ribs and vertebral column are also frequently affected. ES may involve any bone and (less commonly in children) soft tissues.

Chondrosarcoma is the most frequently occurring bone sarcoma of adulthood. The incidence is about 0.2/100 000/year, with the most common age at diagnosis being between 30 and 60 years and the male:female ratio is ~1:1 [5].

Chordomas are rare, arising with an incidence of ~0.5 per million population per year.

diagnosis

The presence of persistent non-mechanical pain in any bone lasting more than a few weeks should cause concern and lead to

further immediate investigation. Swelling will only be present if the tumour has progressed through the cortex and distended the periosteum. Regarding differential diagnosis, malignant bone tumours in children may be confused with benign tumours or (in adults/children) with metastatic disease, both of which outnumber primary malignant bone tumours [6–8]. The most likely diagnosis of a suspected bone tumour is related to age. Before 5 years of age, a destructive bone lesion is most commonly metastatic neuroblastoma or eosinophilic granuloma; above 5 years, it is often a primary bone sarcoma; after 40 years of age, it tends to be metastasis or myeloma [9].

Bone sarcomas are frequently difficult to recognise as malignant by clinicians, radiologists, and pathologists. Therefore, all patients with a suspected primary malignant bone tumour should be referred to a bone sarcoma reference centre or an institution belonging to a specialised bone sarcoma network before biopsy [10–13] [III, A].

The medical history should focus on symptoms such as duration, intensity, and timing of complaints, for example night pain or fracture. Moreover, specific events for bone tumours include prior benign/malignant lesions, family history, and previous radiotherapy. A recent injury does not rule out a malignant tumour and must not prevent appropriate diagnostic procedures. All patients should have a full physical examination. Specific attention should be given to the size, consistency of the swelling, its location and mobility, the relation of swelling to the involved bone, and the presence of regional/local lymph nodes. Conventional radiographs in two planes should always be the first investigation. When the diagnosis of malignancy cannot be excluded with certainty on radiographs, the next imaging step is magnetic resonance imaging (MRI) of the whole compartment with adjacent joints, which is the best modality for local staging of extremity and pelvic tumours [14]. Computed tomography (CT) should be used only in the case of diagnostic problems or doubt, to visualise more clearly calcification, periosteal bone formation or cortical destruction.

The biopsy of a suspected primary malignant bone tumour should be carried out at the reference centre by the surgeon who is to carry out the definitive tumour resection or a radiologist member of the team [10–13]. The principles of the biopsy are:

- there should be minimal contamination of normal tissues;
- in many situations, core-needle biopsies (taken under imaging control) are an appropriate alternative to open biopsy;

*Correspondence to: ESMO Guidelines Working Group, ESMO Head Office, Via L. Taddei 4, CH-6962 Viganello-Lugano, Switzerland.
E-mail: clinicalguidelines@esmo.org

[†]Approved by the ESMO Guidelines Working Group: March 2010, last update July 2014. This publication supersedes the previously published version—Ann Oncol 2012; 23 (Suppl 7): vii100–vii109.

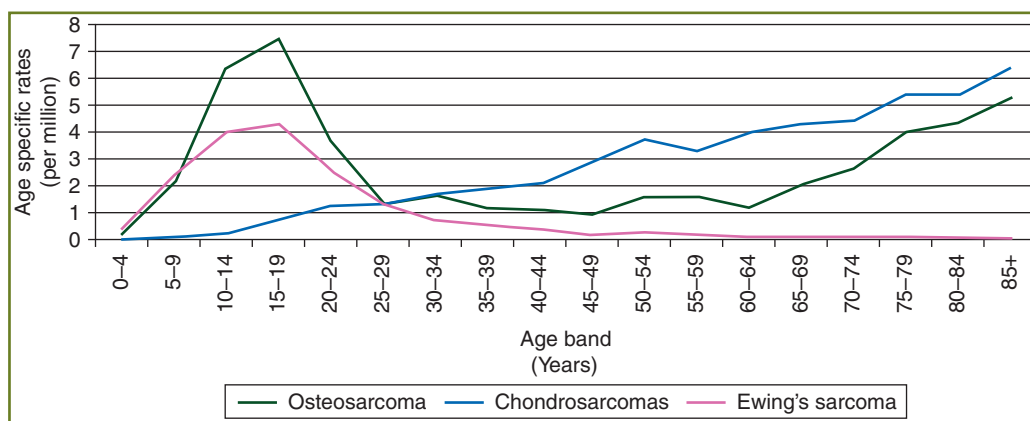


Figure 1. Variations in age-specific incidence rates with morphology, England, 1998–2007. http://www.ncin.org.uk/publications/data_briefings/bone_sarcomas_incidence_and_survival.aspx.

- adequate sampling of representative areas for histology must be assured;
- samples should always be sent for microbiological culture in all cases entailing a potential differential diagnosis;
- samples must be interpreted by an experienced pathologist with the collaboration of a radiologist;
- the request form should contain sufficient details for the pathologist including: the site of the tumour, the patient's age, and the radiological imaging.

If an open biopsy is done, it should be carried out using a longitudinal incision. To be sure that the biopsy location is adequate and the tissue is representative, it is recommended to make X-rays of the biopsy location and sometimes undertake a frozen section in case more material is required. In aggressive and malignant tumours of bone, the biopsy tract must be considered to be contaminated with tumour and must be removed together with the resection specimen to avoid local recurrences, including the possible channels through which drains have been placed. Biopsy tracts should be clearly marked by means of a small incision or ink tattoo to ensure that the location can be recognised at the time of the definitive procedure. In cases of spinal column involvement, laminectomy or decompression should be avoided unless necessary to relieve spinal cord compression. Samples should be quickly submitted for pathological assessment, ideally within half an hour; upon arrival, and before formalin fixation, tumour imprints (touch preps) can be taken (useful for tumour-specific translocation by fluorescence *in situ* hybridisation, FISH), and tissue/cell suspensions should be kept frozen in cryomolds. A further option is to establish primary cell cultures for cytogenetics and other studies. The collection of fresh frozen tissue and tumour imprints (touch preps) is encouraged, because new molecular pathology assessments could be made at a later stage in the patient's interest. Informed consent for tumour banking should be sought, enabling later analyses and research, as long as this is allowed by existing regulations. The nature of the bone specimen received for pathology reporting should be recorded, i.e. needle biopsy, curettage, and excision (e.g. segmental resection, limb salvage amputation, or other complex resection, such as a hemipelvectomy). It is usually necessary to decalcify a bone tumour biopsy. The

pathologist should receive information regarding the clinical/radiological context in which the tumour has arisen, relevant observations made at the time of surgery and whether the patient has received preoperative chemotherapy. The size (measured in three dimensions in mm) of the tumour in the resected bone should be noted.

The histological features of the tumour should be described and the tumour type (and subtype) specified according to the 2013 World Health Organization (WHO) Classification [15].

The pathology report should describe the extent of local tumour spread, including involvement of specific anatomical compartments. It should be noted whether the resection margins are clear or involved by tumour and the distance (in mm) of tumour from the nearest resection margin measured. The results of relevant ancillary investigations (e.g. immunohistochemistry) should be recorded [16]. The tumour should be classified using Systematic Nomenclature of Medicine (SNOMED) or International Classification of Diseases for Oncology (ICD-O) codes.

stage classification and risk assessment

All cases of suspected bone tumours should be discussed on a multidisciplinary basis by the radiologist who has interpreted the imaging, the pathologist who has reviewed the biopsy material, the surgeon, the radiation therapist, and the medical oncologist. This will minimise the risk of errors in diagnosis, staging, risk assessment, and treatment.

Several staging systems for bone tumours are in use [17, 18]. However, none of them is perfect or generally accepted. Generally, tumour burden and the presence of detectable metastases are the two main factors which are taken into consideration in the clinical staging of these diseases.

General staging should be carried out to assess the extent of distant disease, including bone scintigraphy, chest radiographs, and CT [19]. Whole-body MRI and positron emission tomography (PET)/CT or PET/MRI are under evaluation both for staging and treatment response evaluation [20]. Additional appropriate imaging studies and biopsies can be taken from

suspicious sites, as the exact staging of the disease has an impact on treatment and outcome [III, B].

No specific laboratory tests for the diagnosis of bone sarcoma are available. However, some are useful in the follow-up in ES and osteosarcoma and may also be of prognostic value, such as alkaline phosphatase (AP) and lactate dehydrogenase (LDH) [21, 22].

A pathological fracture may lead to the dissemination of tumour cells into surrounding tissues and increase the risk of local recurrence. In the case of an existing pathological fracture in a possible primary malignant bone tumour, adequate imaging should be carried out, including MRI followed by biopsy. In cases of fracture, internal fixation is contraindicated as it disseminates tumour further into both bone and soft tissues and increases the risk of local recurrence. External splintage is recommended, along with appropriate pain control. In patients with weakened bone apparent at presentation, there may be a strong case for immobilising the part following biopsy, usually by application of an external splint. Chemotherapy treatment can result in renal, cardiac, and auditory dysfunction, and patients undergoing this treatment must have baseline renal function testing and assessment of cardiac function as well as an audiogram (in the case of treatment with platinum derivatives). Sperm storage is recommended for male patients of reproductive age. For female patients, a fertility physician should be consulted for available options.

treatment

As malignant primary bone tumours are rare cancers, and as management is complex, the accepted standard is treatment at reference centres and/or within reference networks able to provide access to the full spectrum of care [IV, A]. In these centres/networks, therapy is usually given within the framework of prospective, often collaborative, clinical studies, or established treatment protocols. In the case of high-grade osteosarcoma, ES, or pleomorphic sarcoma, following biopsy proven-diagnosis, primary chemotherapy is indicated, preferably within the framework of (inter)national trials.

osteosarcoma

Osteosarcoma usually arises in the metaphysis of a long bone, most commonly around the knee. Involvement of the axial skeleton and craniofacial bones is primarily observed in adults.

Conventional osteosarcoma, a high-grade malignancy, accounts for 75% of all high-grade osteosarcomas. Low-grade central and parosteal osteosarcoma are low-grade malignancies, whereas periosteal osteosarcoma is an intermediate-grade chondroblastic osteosarcoma. Adverse prognostic or predictive factors include detectable primary metastases, axial or proximal extremity tumour site, large tumour size, elevated serum AP or LDH, and older age [21] [III, B]. Staging should include local imaging studies, as outlined in the following text. Curative treatment of high-grade osteosarcoma consists of chemotherapy and surgery [I, A].

Compared with surgery alone, multimodal treatment of high-grade localised osteosarcoma increases disease-free survival probabilities from only 10%–20% to >60%. In general, chemotherapy is administered before and after surgery, although a

formal proof that giving chemotherapy preoperatively improves the outcome *per se* is lacking. The extent of histological response to preoperative chemotherapy predicts survival [21, 23, 24]. Low-grade central and parosteal osteosarcoma are malignancies with a lower metastatic potential, which are treated by surgery alone [III, B]. Although chemotherapy has been used for periosteal osteosarcomas, no benefit for chemotherapy was shown in two retrospective analyses [25, 26]. Current prospective trials evaluate whether altering postoperative chemotherapy in poor responders to preoperative systemic therapy improves treatment outcome.

Surgery should be carried out by a surgical team familiar with the wide range of surgical reconstructive options. The goal of surgery is to safely remove the tumour and yet preserve as much function as possible, striving to obtain adequate surgical margins as narrower margins are associated with an increased risk of local recurrence [24]. Most patients should be considered candidates for limb salvage. In principle, intralesional or marginal margins increase the local relapse rate, which is associated with reduced overall survival (OS). Thus, good margins are the first goal of surgery [III, B]. Areas where there is suspicion of close margins should be marked on the surgical specimen sent to pathology.

Pathological fracture does not necessarily require amputation. In chemosensitive tumours, primary neoadjuvant chemotherapy can be used with the expectation that a good response will allow the fracture haematoma to contract and allow subsequent resection of the tumour and the involved soft tissues. In patients with a poor response to chemotherapy or in tumours unlikely to respond to chemotherapy, early surgery obtaining wide margins should be considered; in some cases, this may require amputation [27].

Doxorubicin, cisplatin, high-dose methotrexate, ifosfamide, and etoposide have anti-tumour activity in osteosarcoma [28–31] [I, A]. Doxorubicin, cisplatin, and high-dose methotrexate are most frequently used as the basis of treatment [31] [II, A]. These drugs should be administered with adequate supportive care by experienced paediatric oncologists or medical oncologists in reference institutions with appropriate infrastructure and a multidisciplinary treatment approach [29]. A variety of pre- and post-operative combinations are used in common practice and in clinical trials. Most current protocols include a period of preoperative chemotherapy, to facilitate local surgical treatment and allow the assessment of tumour response, although this has not been proven to entail a survival benefit over postoperative chemotherapy alone [32, 33] [I, B]. Treatment is commonly given over periods of 6–10 months [31]. Whenever possible, patients with osteosarcoma should receive chemotherapy in the context of prospective trials. Immune modulation has been attempted with some agents, e.g. interferon [34] and muramyl tripeptide. Muramyl tripeptide added to postoperative chemotherapy was associated with a substantial advantage in OS and a non-significant trend in event-free survival in one large randomised trial [35, 36] [II, C]. Muramyl tripeptide has been approved in Europe for patients <30 years of age with completely resected localised osteosarcoma. There is no consensus in the sarcoma community on the use of this drug, because of weaknesses of the single trial available [35]. Further studies are definitely needed to identify the subgroup of patients who could benefit.

When tumour response assessment before surgery is clinically doubtful and relevant for clinical decision-making, dynamic MRI is reliable, but requires sequential scans to evaluate change in tumour vascularity [37, 38] [III B]. Tumour response is often apparent only after several cycles of chemotherapy. The assessment of MRI peritumoural oedema is helpful: its disappearance is a sign of good treatment response [37].

In general, there is no indication for radiation therapy, but there are anatomical locations in which the possibility of complete surgical resection is limited. In these cases, radiation therapy may be an option to try to extend the progression-free interval. New radiation therapy techniques (e.g. proton beam and carbon ion therapy) may extend indications.

The multimodal treatment principles detailed above were generated in children, adolescents, and young adults with high-grade central osteosarcoma, but also relate to adults at least up to the age of 60 [39] [III, B]. Older patients (>40 years) may require tailored regimens, especially as far as high-dose methotrexate is concerned. Doxorubicin and cisplatin are the most active drugs, with the cumulative dose of anthracycline being a critical factor.

High-grade craniofacial osteosarcoma should be treated the same way as high-grade osteosarcoma of other locations, although evidence is lacking due to the absence of selective clinical studies in this patient population [V, B]. Proton beam/carbon ion radiation therapy may be considered within clinical studies when complete surgery is unfeasible. Primary metastatic osteosarcoma patients are treated with a curative intent along the principles of non-metastatic osteosarcomas [40]. In fact, there are subsets of patients who can have a very similar or even identical prognosis to that of localised disease, provided surgical removal of all known metastatic deposits is achievable [41] [III, B]. Approximately 25% of all patients with primary metastatic osteosarcoma and >40% of those who achieve a complete surgical remission become long-term survivors.

The management of recurrent osteosarcoma needs to take into account the timing of recurrence/metastases, number of metastases, and site of metastases. The treatment of recurrent osteosarcoma is primarily surgical in the case of isolated lung metastases. Complete removal of all metastases must be attempted [III, B], as the disease is otherwise almost universally fatal, while more than a third of patients with a second surgical remission survive for >5 years [42]. Even patients with multiple recurrences may be cured as long as recurrences are resectable, and repeated thoracotomies are often warranted [42] [III, B]. CT scan can both over- and underestimate the number of metastases.

The role of second-line chemotherapy for recurrent osteosarcoma is much less well defined than that of surgery and there is no accepted standard regimen. Treatment choice may take into account the prior disease-free interval, and often includes ifosfamide ± etoposide ± carboplatin, and other active drugs (e.g. gemcitabine and docetaxel; sorafenib). In the two largest reported series, the use of second-line chemotherapy correlated with limited prolongation of survival in patients with inoperable metastatic recurrences, while a positive correlation in operable disease was observed in only one of the two [41, 42]. Radiation therapy (including Samarium) may have a role in palliation [43]. In general, despite second-line treatment, the prognosis of

recurrent disease has remained poor, with long-term post-relapse survival of <20%.

Ewing sarcoma

ES is a small, blue, round-cell tumour, periodic acid-Schiff positive, and CD99(MIC2)-positive. All ESs are high-grade tumours. They can arise both from bone and soft tissues, displaying the same behaviour in principle.

The definitive diagnosis is made by biopsy, providing a sufficient material for conventional histology, immunohistochemistry, molecular pathology, and biobanking. Molecular biology studies have shown that almost all of these tumours share a common gene rearrangement involving the EWS gene on chromosome 22 [44, 45]. In most cases, this involves a reciprocal translocation t(11;22)(q24;q12) [46], but t(21;22)(q22;q12) [47, 48] and others may also occur [t(7;22), t(17;22), and t(2;22) translocations and inv(22)]. Although most ES can be recognised with classical haematoxylin and eosin (H&E) and immunohistochemistry including CD99, EWS translocation detection is mandatory when the clinical-pathological presentation is unusual, or the histological diagnosis is doubtful [II, B]. A reference laboratory for ES diagnosis should have both FISH and reverse transcription polymerase chain reaction (RT-PCR) available [48]. The laboratory is strongly recommended to be enrolled in an external quality assurance programme. RT-PCR is the investigation of choice when frozen tissue is available, and FISH is a good choice only when formalin-fixed paraffin-embedded tissue or touch preps (imprints) are available. There are several commercial sources for EWS break-apart probes. Assays using EWS break-apart probes do not detect EWS-FLI1 fusions, but only EWS rearrangements, which should not be a problem when interpreted in the appropriate clinical and pathological context. However, differential diagnosis versus other sarcomas carrying EWS rearrangements may be challenging.

Bone marrow biopsies and aspirates from sites distant to the primary or known metastatic lesions may be considered, in the face of a very low incidence of bone marrow metastases in localised disease, especially if PET scan was carried out. The added prognostic value of molecular positivity over light microscopic evaluation has not yet been proven [IV, C].

Between 20% and 25% of patients are diagnosed with metastatic disease (10%: lung—10%: bones/bone marrow—5%: combinations, or others) [49, 50]. Staging must be oriented to detect lung, bone, and bone marrow metastases. Multiple bone metastases confer a poorer outcome than lung/pleural metastases (<20% compared with 20%–40% 5-year survival). Other known prognostic factors are tumour size or volume, serum LDH levels, axial localisation, or older age (>15 years). A poor histological response to preoperative chemotherapy and incomplete or no surgery for local therapy are further adverse prognostic factors [II, B] [22, 51–55]. Molecular structure of fusion transcripts has not been shown to be of prognostic value with current treatment protocols. Genomic analysis with the assessment of copy number variation has been shown to be of prognostic value [56, 57]. With surgery or radiotherapy alone, 5-year survival was <10%. With treatment in current multimodality trials including chemotherapy, survival is ~60%–70% in localised

and ~20%–40% in metastatic disease, depending on metastatic sites and burden.

All current trials employ 3–6 cycles of initial combination chemotherapy after biopsy, followed by local therapy, and another 6–10 cycles of chemotherapy usually applied at 2- to 3-week intervals. Treatment duration is thus 10–12 months. Agents considered most active include doxorubicin, cyclophosphamide, ifosfamide, vincristine, dactinomycin, and etoposide [58–62]. Almost all active protocols are based on six-drug combinations of these substances [I, A]. Chemotherapy intensity is positively associated with outcome. High-dose chemotherapy with haematopoietic stem cell transplantation is still investigational in high-risk localised ES [63].

Complete surgical excision, where feasible, is regarded as the best modality of local control, given the higher risk of local recurrence when radiotherapy is used as the sole treatment of the primary tumour. Radiotherapy alone (in the range of 45–60 Gy, depending on location) should be applied if complete surgical excision is impossible. Postoperative radiotherapy should be given in cases of inadequate surgical margins and discussed when histological response in the surgical specimen was poor (i.e. >10% viable tumour cells) [53] [IV, B]. The dose of postoperative radiation therapy is also 45–60 Gy, depending on margins, response, and location. Intralesional surgery must be avoided, as there is no benefit when compared with radiation therapy alone [53]. For extraskelatal ES, postoperative radiation therapy is generally used, with the exception of good prognosis, superficial ES. Change in the size of the soft tissue mass is easily evaluated on MRI and is a good predictor of tumour response [37, 38]. Dynamic MRI is not as reliable as in osteosarcoma [38], as remaining small tumour foci may not be detected. Sequential FDG-PET evaluation might be of additional value [64].

The treatment of adult patients follows the same principles as for ES in typical age groups. However, tolerability of therapies in older patients needs to be taken into account when transferring treatment protocols conceived for children and patients of age ≤40–50 years. The treatment of patients with extraskelatal ES follows the same principles as for bone ES, thus incorporating chemotherapy in all cases as well as postoperative radiation therapy in most cases, with the possible exception of superficial lesions.

Patients with metastases at diagnosis are treated with the same treatment approach as patients with localised disease, although the disease definitely has a worse prognosis. Several non-randomised trials have assessed the value of more intensive, time-compressed, or high-dose chemotherapy approaches, followed by autologous stem cell rescue, with promising results, but evidence of benefit, resulting from trials, is pending [65] [III, C].

In patients with lung metastases, whole-lung irradiation may confer a survival advantage [III, B] [54]. The role of surgical resection of residual metastases is less well defined.

Patients with multiple bone or bone marrow metastases and those with recurrent disease still fare poorly, with 5-year survival rates of ~20%. Despite this, local control of bone metastases with either surgery or radiation therapy is recommended [66].

The only prognostic factor identified in relapsed patients seems to be time to relapse: patients relapsing later than 2 years from initial diagnosis have a better outcome [67] [III, B]. Doxorubicin therapy is usually no longer feasible due to previously achieved

cumulative doses. Chemotherapy regimens in relapse situations are not standardised and are commonly based on alkylating agents (cyclophosphamide and high-dose ifosfamide) [68] in combination with topoisomerase inhibitors (etoposide and topotecan), or irinotecan with temozolomide [III, B] [69, 70] or gemcitabine + docetaxel.

high-grade spindle/pleomorphic sarcomas of bone

Pleomorphic sarcomas of bone comprise a diagnostically heterogeneous group of malignant tumours including undifferentiated pleomorphic sarcoma [16, 71, 72]. They arise in a similar age group to chondrosarcoma, but the skeletal distribution is more like osteosarcoma. They typically present with pain and have a high incidence of fractures at presentation. They represent between 2% and 5% of primary bone malignancies. The true incidence is hard to establish, as the two entities [malignant fibrous histiocytoma (MFH)/fibrosarcoma] exhibit a substantial degree of morphological overlap, also reflected by an inconsistent use of terminology. Males are more frequently affected than females. An association with pre-existing disease (Paget's disease or bone infarct) or history of previous irradiation has been reported. It is not unusual for a spindle cell sarcoma to be found to be either a dedifferentiated chondrosarcoma or osteosarcoma after examining further different sections of the resection.

Pleomorphic sarcomas typically present in older patients with a lytic lesion in bone. In many, the differential diagnosis will be against metastases. Full staging and biopsy are required to reach a diagnosis. Pathological fractures are common and should not undergo fixation before biopsy.

Treatment strategies mimic those of osteosarcoma, with chemotherapy and complete en bloc resection including any soft tissue component. Their sensitivity to chemotherapy is poorly known and studies on specific histologies, as currently defined (especially after reappraisal of histologies previously known as MFH), are highly required.

Radiation therapy may be considered in inoperable lesions.

A global effort to collect these cases would be helpful to establish diagnostic and prognostic criteria as well as recommended treatments.

chondrosarcoma

Most chondrosarcomas arise as primary malignant tumours. The majority are low grade, locally aggressive, non-metastasising tumours (grade I) rather than high grade (grades II–III) [73]. Grade I chondrosarcomas can be labelled atypical chondrogenic tumours, since they usually do not metastasise. One should be aware that grade I chondrosarcomas may be treated with radiation therapy when located at critical sites such as the skull base. Most chondrosarcomas arise centrally in the metaphyseal region of long bones, but they can also develop in flat bones such as pelvis, rib, and scapula. High-grade chondrosarcoma frequently arises in the axial skeleton and long bones. Chondrosarcoma can arise in pre-existing benign lesions such as enchondroma and osteochondroma. In these circumstances, they are referred to as secondary chondrosarcoma and secondary peripheral chondrosarcomas, respectively. The majority of chondrosarcomas are of the conventional subtype, but rarer subtypes include mesenchymal and clear-cell chondrosarcoma [74, 75]. In rare

circumstances, conventional chondrosarcomas can 'dedifferentiate' into a very high-grade tumour with a dismal prognosis: the so-called de-differentiated chondrosarcoma [74, 75]. Most chondrosarcomas are solitary, but they can occur as multiple lesions in patients with multiple osteochondromas and enchondromatosis.

Most chondrosarcomas present with a painless mass. Pain at the site of a cartilaginous lesion may be an indicator of malignancy. In the case of chondrosarcoma, a contrast-enhanced MRI can reveal high-grade areas. This provides a useful guide to the site of biopsy [76]. The differentiation between benign enchondroma or osteochondroma and malignant grade I chondrosarcoma can be difficult. In the phalanges of the hands and feet, malignancy is extremely rare, but in the other long bones central cartilaginous lesions should be considered low-grade chondrosarcoma till proven otherwise [74].

Inoperable, locally advanced, and metastatic high-grade chondrosarcomas have a poor prognosis because of resistance to conventional treatments, such as radiotherapy and chemotherapy [74, 75]. Prognosis depends on histological grade. However, histological classification is subject to variability in interpretation, with grade II and III chondrosarcomas often grouped together even though there is a wide spectrum of outcome [73]. Also, grade I tumours (atypical chondrogenic tumours) are not necessarily curable in all cases, mainly due to problematic local recurrence or progression to high grade. In particular, dedifferentiated chondrosarcomas are aggressive and frequently metastasise [74].

Assessing the grade of chondrosarcomas is difficult and variations in opinions even among experts are common [73]. Low-grade cartilage tumours are unlikely to metastasise, but may recur locally. Grade I central chondrosarcomas in the long bones of the limbs can be managed by curettage with or without adjuvant (e.g. phenol, cement, and cryotherapy) with a high chance of success. Low-grade peripheral chondrosarcomas (arising from osteochondromas) should be surgically excised, aiming to excise the tumour with a covering of normal tissue over it. Higher grade chondrosarcomas and all chondrosarcomas of the pelvis or axial skeleton should be surgically excised with wide margins.

Recent evidence suggests that mesenchymal chondrosarcoma may be chemotherapy sensitive, and may be considered for adjuvant or neoadjuvant therapy [77, 78] [V, B]. Most authorities suggest an Ewing-type chemotherapy regime. There remains uncertainty about chemotherapy sensitivity of dedifferentiated chondrosarcoma, which is often treated as a high-grade bone sarcoma, with therapies which need to be adapted to patient's age [79, 80] [V, C]. There is a very high risk of local recurrence following excision of dedifferentiated chondrosarcoma, particularly in the presence of a pathological fracture. If wide margins cannot be reliably achieved with limb salvage, then amputation should be considered.

The role of radiotherapy in chondrosarcoma is limited, but may be appropriate in highly selected cases or for palliation. Excellent outcomes have been reported for skull base chondrosarcomas with high-dose radiation therapy, including proton beam or carbon ion radiotherapy, achieving 80%–90% local control rates [81].

With regard to chemotherapy, drugs active in sarcomas may prove active in chondrosarcoma, especially high-grade lesions.

There are recent reports of activity of gemcitabine in combination with taxotere [82].

giant cell tumour of bone

Giant cell tumour (GCT) of bone is a relatively rare, benign tumour of the skeleton. Although classified as benign, GCT can be aggressive and recurs locally in up to 50% of cases. Up to 5% of GCTs metastasise to the lungs and spontaneous transformation to a high-grade malignancy occurs in 1%–3% of patients.

Treatment options include intralesional curettage with or without adjuvant or en bloc excision. Recent work has suggested that denosumab, a human monoclonal antibody to RANKL that is overexpressed in GCT, obtains substantial tumour responses in large or unresectable or metastatic GCT. Thus, the agent can be used to achieve cytoreduction allowing potentially curative surgery. It can be used in unresectable disease and rare metastatic disease, where treatment interruption is usually followed by progression, so that treatment needs to be maintained [83].

chordoma

Chordomas are very rare tumours, arising from the remnants of the notochord into the sacrum (50%), skull base (30%), mobile spine (20%); extraskelton cases have also been reported but are extremely rare.

Median age is 60 years, but skull base presentations can also affect a younger population, including children and adolescents.

Chordoma is a low-grade, but locally invasive malignancy. Dedifferentiated cases are observed in 5% of patients. The metastatic potential of chordoma is ~30%. Metastases usually appear late in the natural history of disease, mostly after local recurrence. Chordoma prognosis is more related to local aggressiveness than to metastases. Chordoma is a tumour showing notochordal differentiation. Brachyury is a transcription factor involved in notochord differentiation and is the diagnostic hallmark for conventional chordoma [84]. Dedifferentiated chordomas may lose brachyury expression. Immunohistochemistry positivity for brachyury is strongly recommended to confirm diagnosis.

Due to the rarity and long natural history of the disease, the quality of evidence available for more common tumour types is currently beyond reach for chordoma. In fact, only a few phase II trials are available and most published data are from case series and/or retrospective.

Chordomas need a multidisciplinary approach in referral centres and/or referral networks, with a multidisciplinary team including expert pathologists and radiologists, surgeons familiar with musculo-skeletal tumours and site of surgery, expert radiation oncologists with access to hadron facilities, expert medical oncologists, and a palliative care team. All diagnostic and therapeutic procedures should be discussed in the multidisciplinary expert team.

MRI is the best modality for local staging. CT scan should be used in the case of diagnostic doubt. Chordoma should be differentiated from benign notochordal lesions and, if radiological appearance is typical for these, biopsy is not recommended unless the lesion changes with time [85].

Preoperative core-needle biopsy is recommended. The biopsy track needs to be included in the surgical resection. In the case

of skull base chordoma, preoperative biopsy can be avoided in selected cases.

Tumour location is the most important variable to define the primary tumour treatment. The quality of surgical margins is the most important prognostic factor. En bloc R0 resection is standard treatment, when it is feasible and sequelae are acceptable/accepted by the patient, with an expected 5-year recurrence-free survival = 50%. If en bloc R0 resection is not feasible, definitive radiation therapy alone should always be considered as a valid alternative. Local relapse has extremely poor survival rates and local control is rarely achievable. Supportive care should be incorporated into the treatment from the beginning.

For skull base and upper cervical tract chordoma, R1–R2 surgery plus high-dose radiation therapy is the treatment of choice [86–88].

For sacral chordoma, surgery should definitely be offered as the first choice in case chordoma arises from S4 and below. Surgery should always be discussed in the context of other alternatives for tumours originating above S3, since surgery is always followed by important neurological sequelae. Surgery is the primary standard choice for tumours originating from S3, especially if the preservation of S2 roots is possible, as it may result in some neurological recovery (40% of cases) [89–91].

Hadrons, i.e. high-dose protons or carbon ions, are superior to photons physically and in terms of irradiation of non-target lesions, although no randomised trials are available to assess the benefit of hadrons compared with photons in chordoma. Since hadrons allow lower doses to be given to normal tissues, they should be considered the treatment of choice. Advanced technology photons could be used in the case of unavailability or non-accessibility of protons and ions, and every time they show similar dose distribution to the target and critical structures. Due to the relative radiation resistance of chordomas, a high-dose up to at least 74 GyE in conventional fractionation (1.8–2 GyE) for photon- and proton-therapy is required [81, 92, 93].

Indications for definitive radiation therapy are: unresectable disease; inoperable patients; or neurological impairment not accepted by the patient. Radiation therapy should be considered in the case of R2 or R1 resections. The use of adjuvant/neoadjuvant radiation therapy needs to be discussed with the single patient and prospective studies encouraged.

Patients who have local recurrence are unlikely to be cured by any local salvage treatment. In the case of local relapse, the choice of treatment can include surgery and/or radiation therapy and/or systemic treatment, balancing morbidity and quality of life.

For oligometastatic disease, surgery/radiofrequency ablations/stereotactic radiation of metastases can be considered in selected cases. Chemotherapy is inactive. An exception can be high-grade dedifferentiated chordoma (anecdotal responses to chemotherapy have been reported).

There is uncontrolled evidence that imatinib is beneficial in advanced chordoma in terms of progression-free survival and mainly non-dimensional tumour responses [94]. Its role within the treatment strategy deserves further evaluation.

There are data on the activity of epidermal growth factor receptor and vascular endothelial growth factor receptor inhibitors. Prospective studies are ongoing.

follow-up

Follow-up is designed to detect either local recurrence or metastatic disease at a time when early treatment is still possible and might be effective. Follow-up of high-grade tumours should include both a physical examination of the tumour site and assessment of the function and possible complications of any reconstruction. Local imaging and chest X-ray/CT should be the norm. Though strict rules cannot be provided in the absence of any formal validation, a recommended follow-up policy may foresee intervals between checks after the completion of chemotherapy every 2–3 months for the first 2 years; every 2–4 months for years 3–4; every 6 months for years 5–10, and thereafter every 6–12 months according to local practice and other factors.

In the case of low-grade bone sarcoma, the frequency of follow-up visits may be lower (e.g. 6 months for 2 years and then annually). Late metastases as well as local recurrences and functional deficits may occur >10 years after diagnosis and there is no universally accepted stopping point for tumour surveillance.

In ES, where osseous metastases are likely, isotope bone scanning can be used in addition. More modern techniques (e.g. PET or whole-body MRI) require further evaluation. It is important to evaluate the long-term toxicity effect of chemotherapy and radiotherapy if appropriate. Monitoring for late effect should be continued for >10 years after treatment, depending on the chemotherapy protocol and radiation used and in conjunction with late effects services when available.

Secondary cancers may arise in survivors of bone sarcomas, either related to, or independent of, irradiation. Secondary leukaemia, particularly acute myeloid leukaemia, may rarely be observed following chemotherapy, as early as 2–5 years after treatment.

note

Levels of evidence and grades of recommendation have been applied using the system shown in Table 1. Statements without grading were considered justified standard clinical practice by the panel members.

consensus panel ESMO Guidelines 2014

These Clinical Practice Guidelines have been developed following a consensus process based on a consensus event organised by ESMO in Milan, Italy, in December 2013 and refined by July 2014. This involved experts from the community of the European sarcoma research groups and ESMO faculty. Their names are indicated hereafter. The text reflects an overall consensus among them, although each of them may not necessarily find it consistent with his/her own views. The panel worked on the text of ESMO Guidelines of previous years, whose authorship should also be credited.

- Paolo G. Casali, Italy (*Moderator*)
- Jean-Yves Blay, France (*Moderator*)
- Alexia Bertuzzi, Ireland
- Stefan Bielack, Germany
- Bodil Bjerkeheggen, Norway

Table 1. Levels of evidence and grades of recommendation (adapted from the Infectious Diseases Society of America–United States Public Health Service Grading System^a)

Levels of evidence	
I	Evidence from at least one large randomised, controlled trial of good methodological quality (low potential for bias) or meta-analyses of well-conducted randomised trials without heterogeneity
II	Small randomised trials or large randomised trials with a suspicion of bias (lower methodological quality) or meta-analyses of such trials or of trials with demonstrated heterogeneity
III	Prospective cohort studies
IV	Retrospective cohort studies or case–control studies
V	Studies without control group, case reports, experts opinions
Grades of recommendation	
A	Strong evidence for efficacy with a substantial clinical benefit, strongly recommended
B	Strong or moderate evidence for efficacy but with a limited clinical benefit, generally recommended
C	Insufficient evidence for efficacy or benefit does not outweigh the risk or the disadvantages (adverse events, costs, ...), optional
D	Moderate evidence against efficacy or for adverse outcome, generally not recommended
E	Strong evidence against efficacy or for adverse outcome, never recommended

^aBy permission of the Infectious Diseases Society of America [95].

- Sylvie Bonvalot, France
- Ioannis Boukovinas, Greece
- Paolo Bruzzi, Italy
- Angelo Paolo Dei Tos, Italy
- Palma Dileo, UK
- Mikael Eriksson, Sweden
- Alexander Fedenko, Russian Federation
- Andrea Ferrari, Italy
- Stefano Ferrari, Italy
- Hans Gelderblom, Belgium
- Robert Grimer, UK
- Alessandro Gronchi, Italy
- Rick Haas, Netherlands
- Kirsten Sundby Hall, Norway
- Peter Hohenberger, Germany
- Rolf Issels, Germany
- Heikki Joensuu, Finland
- Ian Judson, UK
- Axel Le Cesne, France
- Saskia Litière, Belgium
- Javier Martin-Broto, Spain
- Ofer Merimsky, Israel
- Michael Montemurro, UK
- Carlo Morosi, Italy
- Piero Picci, Italy
- Isabelle Ray-Coquard, France
- Peter Reichardt, Germany
- Piotr Rutkowski, Poland
- Marcus Schlemmer, Germany
- Silvia Stacchiotti, Italy
- Valter Torri, Italy
- Annalisa Trama, Italy
- Frits Van Coevorden, Netherlands
- Winette Van der Graaf, Netherlands
- Daniel Vanel, Italy
- Eva Wardelmann, Germany

A Consensus meeting was specifically held on chordoma, whose output was a separate position paper but which also contributed to the Chordoma paragraph of the ESMO Guidelines. In addition to some of the above mentioned experts, it was also made up by the following panellists:

- Stephanie Bolle, France
- Rodolfo Capanna, Italy
- Thomas Delaney, USA
- Francesco Doglietto, Italy
- Piero Fossati, Italy
- Lee Jeys, UK
- Bernd Kasper, Germany
- Andreas Leithner, Austria
- Ole-Jacob Norum, Norway
- Stefano Radaelli, Italy
- Susanne Scheipl, Austria
- Elena Tamborini, Italy
- Mathias Uhl, Germany
- Carmen L.A. Vlegger-Lankamp, Netherlands

acknowledgements

We deeply thank Barbara Doré and Estelle Lecointe (from SPAEN), and Hans Keulen (from Chordoma Foundation), who observed the consensus conference as patient representatives.

conflict of interest

Stefan Bielack declared: consultancy/advisory board/speakers bureau from Merck, IDM/Takeda, Roche, Celgene, Bayer, and Chugai. Sylvie Bonvalot declared: travel grants from PharmaMar, Nanobiotix, and honoraria from Novartis. Paolo G. Casali declared: consultancy/honoraria: Amgen Domplé, ARIAD, Bayer, GlaxoSmithKline, Infinity, Janssen Cilag, Merck Sharp & Dohme, Novartis, Pfizer, PharmaMar, Sanofi. Angelo Paolo

Dei Tos declared: speakers' bureau: Novartis Oncology, Pfizer, GlaxoSmithKline, and PharmaMar. Thomas Delaney has reported that he owned common stock in GlaxoSmithKline that was sold in early 2014; membership of the Amgen Giant Cell Tumor Global Scientific Advisory Board and received compensation for attending a meeting of this advisory board in 2012. Mikael Eriksson declared: honoraria from Novartis, Swedish Orphan Biovitrum, GlaxoSmithKline, Merck Sharp & Dohme, and Pfizer. Alexander Fedenko declared: speakers' bureau: Johnson & Johnson, GlaxoSmithKline, and Roche. Stefano Ferrari declared: speakers' honoraria from Takeda; advisory board for Amgen; research grants from Mulmed, Amgen, and Morphotek. Hans Gelderblom declared research grants from Novartis, Pfizer, PharmaMar, GlaxoSmithKline, Eisai, and Bayer. Robert Grimer declared: research grant: Amgen. Alessandro Gronchi declared: advisory board: Novartis; honoraria: Novartis and Pfizer. Rolf Issels declared: consultancy/honoraria: PharmaMar, Bayer, and Therm Med. Heikki Joensuu declared: research funding to institute from Novartis. Bernd Kasper declared: consultancy/honoraria: Novartis, GlaxoSmithKline, and PharmaMar; research grants: PharmaMar. Axel Le Cesne declared: honoraria: Novartis, PharmaMar, GlaxoSmithKline, and Pfizer. Javier Martin-Broto declared advisory boards for GlaxoSmithKline, Novartis, and PharmaMar. Ofer Merimsky declared: speakers' honoraria: GlaxoSmithKline and Lilly; advisory board: Boehringer Ingelheim and Medison; research grant: Piero Picci declared advisory board for Takeda. Piotr Rutkowski declared honoraria from Novartis, Pfizer, Bristol-Myers Squibb, Roche, and GlaxoSmithKline; advisory board for Novartis, GlaxoSmithKline, Merck Sharp & Dohme, and Bayer. Susanne Scheipl declared grants and personal fees from the Chordoma Foundation, as well as non-financial support from GlaxoSmithKline, and non-financial support from PharmaMar in course of her current research project on chordoma at the UCL Cancer Institute in London. Marcus Schlemmer declared: honoraria from Novartis, Pfizer, and Teva; research grants from Novartis. Silvia Stacchiotti declared: research grants: Novartis, Pfizer, PharmaMar, GlaxoSmithKline, Amgen, and Bayer. Frits Van Coevorden declared travel grants from Novartis and PharmaMar. Carmen Vleggeert-Lankamp declared research grants from Medtronic, B Braun, Paradigm Spine and the Eurospine Foundation, the National Health Organization, Netherlands, and the Dutch Brain Foundation. Winette Van der Graaf declared: research funding from GlaxoSmithKline, Novartis and Pfizer. The following authors have declared no potential conflicts of interest: Alexia Bertuzzi, Bodil Bjerkehagen, Stephanie Bolle, Ioannis Boukovinas, Rodolfo Capanna, Palma Dileo, Francesco Doglietto, Andrea Ferrari, Piero Fossati, Rick Haas, Kirsten Sundby Hall, Lee Jeys, Andreas Leithner, Saskia Litière, Michael Montemurro, Carlo Morosi, Stefano Radaelli, Isabelle Ray-Coquard, Elena Tamborini, Valter Torri, Daniel Vanel and Eva Wardelmann. The other authors have not reported any potential conflicts of interest.

references

1. Stiller CA, Craft AW, Corazzari I. EURO CARE Working Group. Survival of children with bone sarcoma in Europe since 1978: results from the EURO CARE study. *Eur J Cancer* 2001; 37: 760–766.
2. Hansen MF, Seton M, Merchant A. Osteosarcoma in Paget's disease of bone. *J Bone Miner Res* 2006; 21(Suppl 2): 58–63.
3. Fuchs B, Pritchard DJ. Etiology of osteosarcoma. *Clin Orthop Relat Res* 2002; 40–52.
4. Cotterill SJ, Parker L, Malcolm AJ et al. Incidence and survival for cancer in children and young adults in the North of England, 1968–1995: a report from the Northern Region Young Persons' Malignant Disease Registry. *Br J Cancer* 2000; 83: 397–403.
5. Bovée JV, Cleton-Jansen AM, Taminiau AH, Hogendoorn P. Emerging pathways in the development of chondrosarcoma of bone and implications for targeted treatment. *Lancet Oncol* 2005; 6: 599–607.
6. van den Berg H, Kroon HM, Slaar A, Hogendoorn P. Incidence of biopsy-proven bone tumors in children: a report based on the Dutch pathology registration 'PALGA'. *J Pediatr Orthop* 2008; 28: 29–35.
7. Hauben EI, Hogendoorn PCW. Epidemiology of primary bone tumors and economical aspects of bone metastases. In Heymann D (ed), *Bone Cancer. Progression and Therapeutic Approaches*, 1st edition. London: Academic Press 2009; 3–8.
8. Malhas AM, Grimer RJ, Abudu A et al. The final diagnosis in patients with a suspected primary malignancy of bone. *J Bone Joint Surg Br* 2011; 93: 980–983.
9. Grimer RJ, Briggs TW. Earlier diagnosis of bone and soft-tissue tumors. *J Bone Joint Surg Br* 2010; 92: 1489–1492.
10. Enneking WF. The issue of the biopsy. *J Bone Joint Surg Am* 1982; 64: 1119–1120.
11. Andreou D, Bielack SS, Carrle D et al. The influence of tumor- and treatment related factors on the development of local recurrence in osteosarcoma after adequate surgery. An analysis of 1355 patients treated on neoadjuvant Cooperative Osteosarcoma Study Group protocols. *Ann Oncol* 2011; 22: 1228–1235.
12. van den Berg H, Slaar A, Kroon HM et al. Results of diagnostic review in pediatric bone tumors and tumorlike lesions. *J Pediatr Orthop* 2008; 28: 561–564.
13. Mankin HJ, Lange TA, Spanier SS. The hazards of biopsy in patients with malignant primary bone and soft-tissue tumors. *J Bone Joint Surg Am* 1982; 64: 1121–1127.
14. Meyer JS, Nadel HR, Marina N et al. Imaging guidelines for children with Ewing sarcoma and osteosarcoma: a report from the Children's Oncology Group BoneTumor Committee. *Pediatr Blood Cancer* 2008; 51: 163–170.
15. WHO Classification of Tumors. In Fletcher CDM, Bridge JA, Hogendoorn PCW, Mertens F (eds), *WHO Classification of Tumours of Soft Tissue and Bone*. Lyon: IARC 2013.
16. Abdul-Karim FW, Bauer TW, Kilpatrick SE et al. Recommendations for the reporting of bone tumors. *Association of Directors of Anatomic and Surgical Pathology. Hum Pathol* 2004; 35: 1173–1178.
17. Enneking WF, Spanier SS, Goodman MA. A system for the surgical staging of musculoskeletal sarcoma. *Clin Orthop Relat Res* 1980; 153: 106–120.
18. Sobin LH, Gospodarowicz MK, Wittekind CH (eds). *TNM Classification of Malignant Tumors*, 7th edition. Oxford: Wiley-Blackwell 2009.
19. Picci P, Vanel D, Briccoli A et al. Computed tomography of pulmonary metastases from osteosarcoma: the less poor technique. A study of 51 patients with histological correlation. *Ann Oncol* 2001; 12: 1601–1604.
20. Benz MR, Tchekmedyian N, Eilber FC et al. Utilization of positron emission tomography in the management of patients with sarcoma. *Curr Opin Oncol* 2009; 21: 345–351.
21. Bramer JA, van Linde JH, Grimer RJ, Scholten RJ. Prognostic factors in localized extremity osteosarcoma: a systematic review. *Eur J Surg Oncol* 2009; 35: 1030–1036.
22. Leavey PJ, Collier AB. Ewing sarcoma: prognostic criteria, outcomes and future treatment. *Expert Rev Anticancer Ther* 2008; 8: 617–624.
23. Bielack SS, Kempf-Bielack B, Delling G et al. Prognostic factors in high-grade osteosarcoma of the extremities or trunk: an analysis of 1702 patients treated on neoadjuvant cooperative osteosarcoma study group protocols. *J Clin Oncol* 2002; 20: 776–790.
24. Picci P, Sangiorgi L, Rougraff BT et al. Relationship of chemotherapy-induced necrosis and surgical margins to local recurrence in osteosarcoma. *J Clin Oncol* 1994; 12: 2699–2705.
25. Grimer RJ, Bielack S, Flege S et al. Periosteal osteosarcoma—a European review of outcome. *Eur J Cancer* 2005; 41: 2806–2811.

26. Cesari M, Alberghini M, Vanel D et al. Periosteal osteosarcoma: a single institution experience. *Cancer* 2011; 117: 1731–1735.
27. Bramer JA, Abudu AA, Grimer RJ et al. Do pathological fractures influence survival and local recurrence rate in bony sarcomas? *Eur J Cancer* 2007; 43: 1944–1951.
28. Ferrari S, Smeland S, Mercuri M et al. Neoadjuvant chemotherapy with high dose ifosfamide, high-dose methotrexate, cisplatin, and doxorubicin for patients with localized osteosarcoma of the extremity: a joint study by the Italian and Scandinavian Sarcoma Groups. *J Clin Oncol* 2005; 23: 8845–8852.
29. Arndt CA, Crist WM. Common musculoskeletal tumors of childhood and adolescence. *N Engl J Med* 1999; 341: 342–352.
30. Lewis IJ, Nooij MA, Whelan J et al. Improvement in histologic response but not survival in osteosarcoma patients treated with intensified chemotherapy: a randomized phase III trial of the European Osteosarcoma Intergroup. *J Natl Cancer Inst* 2007; 99: 112–128.
31. Carrle D, Bielack SS. Current strategies of chemotherapy in osteosarcoma. *Int Orthop* 2006; 30: 445–451.
32. Bielack SS, Machatschek JN, Flege S, Jürgens H. Delaying surgery with chemotherapy for osteosarcoma of the extremities. *Expert Opin Pharmacother* 2004; 5: 1243–1256.
33. Goorin AM, Schwartzentruber DJ, Devidas M et al. Presurgical chemotherapy compared with immediate surgery and adjuvant chemotherapy for non metastatic osteosarcoma: Pediatric Oncology Group Study POG-8651. *J Clin Oncol* 2003; 21: 1574–1580.
34. Whelan J, Patterson D, Perisoglou M et al. The role of interferons in the treatment of osteosarcoma. *Pediatr Blood Cancer* 2010; 54: 350–354.
35. Meyers PA, Schwartz CL, Krailo MD et al. Osteosarcoma: the addition of muramyl tripeptide to chemotherapy improves overall survival—a report from the Children's Oncology Group. *J Clin Oncol* 2008; 26: 633–638.
36. Hunsberger S, Freidlin B, Smith MA. Complexities in interpretation of osteosarcoma clinical trial results. *J Clin Oncol* 2008; 26: 3103–3104.
37. van der Woude HJ, Bloem JL, Hogendoorn PC. Preoperative evaluation and monitoring chemotherapy in patients with high-grade osteogenic and Ewing's sarcoma: review of current imaging modalities. *Skeletal Radiol* 1998; 27: 57–71.
38. van der Woude HJ, Bloem JL, Verstraete KL et al. Osteosarcoma and Ewing's sarcoma after neoadjuvant chemotherapy: value of dynamic MR imaging in detecting viable tumor before surgery. *AJR Am J Roentgenol* 1995; 165: 593–598.
39. Grimer RJ, Cannon SR, Taminiau AM et al. Osteosarcoma over the age of forty. *Eur J Cancer* 2003; 39: 157–163.
40. Kager L, Zoubek A, Pötschger U et al. Primary metastatic osteosarcoma: presentation and outcome of patients treated on neoadjuvant Cooperative Osteosarcoma Study Group protocols. *J Clin Oncol* 2003; 21: 2011–2018.
41. Ferrari S, Briccoli A, Mercuri M et al. Postrelapse survival in osteosarcoma of the extremities: prognostic factors for long-term survival. *J Clin Oncol* 2003; 21: 710–715.
42. Kempf-Bielack B, Bielack SS, Jürgens H et al. Osteosarcoma relapse after combined modality therapy: an analysis of unselected patients in the Cooperative Osteosarcoma Study Group (COSS). *J Clin Oncol* 2005; 23: 559–568.
43. Berger M, Grignani G, Giostra A et al. 153 Samarium-EDTMP administration followed by hematopoietic stem cell support for bone metastases in osteosarcoma patients. *Ann Oncol* 2012; 23: 1899–1905.
44. Aurias A, Rimbaut C, Buffe D et al. Translocation involving chromosome 22 in Ewing's sarcoma. A cytogenetic study of four fresh tumors. *Cancer Genet Cytogenet* 1984; 12: 21–25.
45. Turc-Carel C, Philip I, Berger MP et al. Chromosome study of Ewing's sarcoma (ES) cell lines. Consistency of a reciprocal translocation t(11;22)(q24;q12). *Cancer Genet Cytogenet* 1984; 12: 1–19.
46. Zoubek A, Pfeleiderer C, Salzer-Kuntschik M et al. Variability of EWS chimaeric transcripts in Ewing tumors: a comparison of clinical and molecular data. *Br J Cancer* 1994; 70: 908–913.
47. Sorensen PH, Lessnick SL, Lopez-Terrada D et al. A second Ewing's sarcoma translocation, t(21;22), fuses the EWS gene to another ETS-family transcription factor, ERG. *Nat Genet* 1994; 6: 146–151.
48. Machado I, Noguera R, Pellin A et al. Molecular diagnosis of Ewing sarcoma family of tumors: a comparative analysis of 560 cases with FISH and RT-PCR. *Diagn Mol Pathol* 2009; 18: 189–199.
49. Cangir A, Vietti TJ, Gehan EA et al. Ewing's sarcoma metastatic at diagnosis. Results and comparisons of two intergroup Ewing's sarcoma studies. *Cancer* 1990; 66: 887–893.
50. Bernstein ML, Devidas M, Lafreniere D et al. Intensive therapy with growth factor support for patients with Ewing tumor metastatic at diagnosis: Pediatric Oncology Group/Children's Cancer Group Phase II Study 9457—a report from the Children's Oncology Group. *J Clin Oncol* 2006; 24: 152–159.
51. Bacci G, Ferrari S, Bertoni F et al. Prognostic factors in non metastatic Ewing's sarcoma of bone treated with adjuvant chemotherapy: analysis of 359 patients at the Istituto Ortopedico Rizzoli. *J Clin Oncol* 2000; 18: 4–11.
52. Bacci G, Forni C, Longhi A et al. Long-term outcome for patients with non metastatic Ewing's sarcoma treated with adjuvant and neoadjuvant chemotherapies. 402 patients treated at Rizzoli between 1972 and 1992. *Eur J Cancer* 2004; 40: 73–83.
53. Cotterill SJ, Ahrens S, Paulussen M et al. Prognostic factors in Ewing's tumor of bone: analysis of 975 patients from the European Intergroup Cooperative Ewing's Sarcoma Study Group. *J Clin Oncol* 2000; 18: 3108–3114.
54. Paulussen M, Ahrens S, Craft AW et al. Ewing's tumors with primary lung metastases: survival analysis of 114 (European Intergroup) Cooperative Ewing's Sarcoma Studies patients. *J Clin Oncol* 1998; 16: 3044–3052.
55. Pinkerton CR, Bataillard A, Guillo S et al. Treatment strategies for metastatic Ewing's sarcoma. *Eur J Cancer* 2001; 37: 1338–1344.
56. Le Deley MC, Delattre O, Schaefer KL et al. Impact of EWS-ETS fusion type on disease progression in Ewing's sarcoma/peripheral primitive neuroectodermal tumor: prospective results from the cooperative Euro-E.W.I.N.G. 99 trial. *J Clin Oncol* 2010; 28: 1982–1988.
57. van Doorninck JA, Ji L, Schaub B et al. Current treatment protocols have eliminated the prognostic advantage of type 1 fusions in Ewing sarcoma: a report from the Children's Oncology Group. *J Clin Oncol* 2010; 28: 1989–1994.
58. Schuck A, Ahrens S, Paulussen M et al. Local therapy in localized Ewing tumors: results of 1058 patients treated in the CESS 81, CESS 86, and ECESS 92 trials. *Int J Radiat Oncol Biol Phys* 2003; 55: 168–177.
59. Bernstein M, Kovar H, Paulussen M et al. Ewing's sarcoma family of tumors: current management. *Oncologist* 2006; 11: 503–519.
60. Grier HE, Krailo MD, Tarbell NJ et al. Addition of ifosfamide and etoposide to standard chemotherapy for Ewing's sarcoma and primitive neuroectodermal tumor of bone. *N Engl J Med* 2003; 348: 694–701.
61. Nesbit ME, Jr, Gehan EA, Burgert EO, Jr et al. Multimodal therapy for the management of primary, nonmetastatic Ewing's sarcoma of bone: a long term follow-up of the first intergroup study. *J Clin Oncol* 1990; 8: 1664–1674.
62. Paulussen M, Craft AW, Lewis I et al. Results of the ECESS-92 study: two randomized trials of Ewing's sarcoma treatment—cyclophosphamide compared with ifosfamide in standard-risk patients and assessment of benefit of etoposide added to standard treatment in high-risk patients. *J Clin Oncol* 2008; 26: 4385–4393.
63. Ferrari S, Sundby Hall K, Luksch R et al. Nonmetastatic Ewing family tumors: high-dose chemotherapy with stem cell rescue in poor responder patients. Results of the Italian Sarcoma Group/Scandinavian Sarcoma Group III protocol. *Ann Oncol* 2011; 22: 1221–1227.
64. Shapeero LG, Vanel D. Imaging evaluation of the response of high-grade osteosarcoma and Ewing sarcoma to chemotherapy with emphasis on dynamic contrast-enhanced magnetic resonance imaging. *Semin Musculoskelet Radiol* 2000; 4: 137–146.
65. Ladenstein R, Pötschger U, Le Deley MC et al. Primary disseminated multifocal Ewing sarcoma: results of the Euro-EWING 99 trial. *J Clin Oncol* 2010; 28: 3284–3291.
66. Haeusler J, Ranft A, Boelling T et al. The value of local treatment in patients with primary, disseminated, multifocal Ewing sarcoma (PDMES). *Cancer* 2010; 116: 443–450.
67. Stahl M, Ranft A, Paulussen M et al. Risk of recurrence and survival after relapse in patients with Ewing sarcoma. *Pediatr Blood Cancer* 2011; 57: 549–553.

68. Ferrari S, del Prever AB, Palmerini E. Response to high-dose ifosfamide in patients with advanced/recurrent Ewing sarcoma. *Pediatr Blood Cancer* 2009; 52: 581–584.
69. Wagner LM, McAllister N, Goldsby RE et al. Temozolomide and intravenous irinotecan for treatment of advanced Ewing sarcoma. *Pediatr Blood Cancer* 2007; 48: 132–139.
70. Hunold A, Weddeling N, Paulussen M et al. Topotecan and cyclophosphamide in patients with refractory or relapsed Ewing tumors. *Pediatr Blood Cancer* 2006; 47: 795–800.
71. Souhami RL, Tannock I, Hohenberger JC (eds) et al. *Oxford Textbook of Oncology*. Oxford: Oxford University Press 2002.
72. Pakos EE, Grimer RJ, Peake D et al. The 'other' bone sarcomas: prognostic factors and outcomes of spindle cell sarcomas of bone. *J Bone Joint Surg Br* 2011; 93: 1271–1278.
73. Eefting D, Schrage YM, Geirnaerd MJ et al. Assessment of interobserver variability and histologic parameters to improve reliability in classification and grading of central cartilaginous tumors. *Am J Surg Pathol* 2009; 33: 50–57.
74. Gelderblom H, Hogendoorn PC, Dijkstra SD et al. The clinical approach towards chondrosarcoma. *Oncologist* 2008; 13: 320–329.
75. Riedel RF, Larrier N, Dodd L et al. The clinical management of chondrosarcoma. *Curr Treat Options Oncol* 2009; 10: 94–106.
76. Geirnaerd MJ, Hogendoorn PC, Bloem JL et al. Cartilaginous tumors: fast contrast-enhanced MR imaging. *Radiology* 2000; 214: 539–546.
77. Cesari M, Bertoni F, Bacchini P et al. Mesenchymal chondrosarcoma. An analysis of patients treated at a single institution. *Tumori* 2007; 93: 423–427.
78. Dantonello TM, Int-Veen C, Leuschner I et al. Mesenchymal chondrosarcoma of soft tissues and bone in children, adolescents, and young adults: experiences of the CWS and COSS study groups. *Cancer* 2008; 112: 2424–2431.
79. Dickey ID, Rose PS, Fuchs B et al. Dedifferentiated chondrosarcoma: the role of chemotherapy with updated outcomes. *J Bone Joint Surg Am* 2004; 86-A: 2412–2418.
80. Grimer RJ, Gosheger G, Taminiou A et al. Dedifferentiated chondrosarcoma: prognostic factors and outcome from a European group. *Eur J Cancer* 2007; 43: 2060–2065.
81. Noël G, Feuvret L, Ferrand R et al. Radiotherapeutic factors in the management of cervical-basal chordomas and chondrosarcomas. *Neurosurgery* 2004; 55: 1252–1260.
82. Fox E, Patel S, Wathen JK et al. Phase II study of sequential gemcitabine followed by docetaxel for recurrent Ewing sarcoma, osteosarcoma, or unresectable or locally recurrent chondrosarcoma: results of Sarcoma Alliance for Research through Collaboration Study 003. *Oncologist* 2012; 17: 321.
83. Chawla S, Henshaw R, Seeger L et al. Safety and efficacy of denosumab for adults and skeletally mature adolescents with giant cell tumour of bone: interim analysis of an open-label, parallel-group, phase 2 study. *Lancet Oncol* 2013; 14: 901–908.
84. Vujovic S, Henderson S, Presneau N et al. Brachyury, a crucial regulator of notochordal development, is a novel biomarker for chordomas. *J Pathol* 2006; 209: 157–165.
85. Rodallec MH, Feydy A, Larousserie F et al. Diagnostic imaging of solitary tumours of the spine: what to do and say. *RadioGraphics* 2008; 28: 1019–1041.
86. Di Maio S, Rostomily R, Sekhar LN. Current surgical outcomes for cranial base chordomas: cohort study of 95 patients. *Neurosurgery* 2012; 70: 1355–1360.
87. Yasuda M, Bresson D, Chibbaro S et al. Chordomas of the skull base and cervical spine: clinical outcomes associated with a multimodal surgical resection combined with proton-beam radiation in 40 patients. *Neurosurg Rev* 2012; 35: 171–182.
88. Schulz-Ertner D, Karger CP, Feuerhake A et al. Effectiveness of carbon ion radiotherapy in the treatment of skull-base chordomas. *Int J Radiat Oncol Biol Phys* 2007; 68: 449–457.
89. Fuchs B, Dickey ID, Yaszemski MJ et al. Operative management of sacral chordoma. *J Bone Joint Surg Am* 2005; 87: 2211–2216.
90. Stacchiotti S, Casali PG, Lo Vullo S et al. Chordoma of the mobile spine and sacrum: a retrospective analysis of a series of patients surgically treated at two referral centers. *Ann Surg Oncol* 2010; 17: 211–219.
91. Clarke MJ, Dasenbrock H, Bydon A et al. Posterior-only approach for en bloc sacrectomy: clinical outcomes in 36 consecutive patients. *Neurosurgery* 2012; 71: 357–364; discussion 364.
92. Ares C, Hug EB, Lomax AJ et al. Effectiveness and safety of spot scanning proton radiation therapy for chordomas and chondrosarcomas of the skull base: first long-term report. *Int J Radiat Oncol Biol Phys* 2009; 75: 1111–1118.
93. Delaney TF, Liebsch NJ, Pedlow FX et al. Phase II study of high-dose photon/proton radiotherapy in the management of spine sarcomas. *Int J Radiat Oncol Biol Phys* 2009; 74: 732–739.
94. Stacchiotti S, Longhi A, Ferraresi V et al. A phase II study on imatinib in advanced chordoma. *J Clin Oncol* 2012; 30: 914–920.
95. Dykewicz CA. Summary of the guidelines for preventing opportunistic infections among hematopoietic stem cell transplant recipients. *Clin Infect Dis* 2001; 33: 139–144.